

Biochemical and Histological Alteration and Effect of Perfloxacin on Wistar Rats Reproductive Function

¹Eteng, M.U., ¹Ukpanukpong, R.U., ^{1,2}Abolaji, A.O, Eyong, E.U., and ¹Egbung, E.

¹Department of Biochemistry, College of Medical Sciences,
University of Calabar P.M.B 1115 Calabar, Cross River State, Nigeria.

²Department of Biological Sciences, College of Science and
Technology, Covenant University, P.M.B 1023, Canaan Land, Ota, Ogun State, Nigeria.

Abstract: Objectives: The biochemical and histological alteration and effects of Pefloxacin (PF) on wistar rats reproductive function was evaluated. Methods: Sixty four adult wistar rats (180-240 g), of either sex were randomly selected into four study groups. Each group comprised of 16 rats (eight males and eight females), with group I as control while groups II to IV were treatments. Male and female rats of each group were left overnight to mate and gestation day 0 was regarded as day spermatozoa were identified in vaginal smear of female rats. Perfloxacin in dose 11.43 mg/kg body weight in normal saline (vehicle) was administered via oral gavage to both male and female animals of group II, but to only female animals of group III and males of group IV for 14 days. Control animals received 0.5 ml normal saline. In life observation measurements were taken and at the end of drug administration, gestation and parturition periods, the number of births and weight of litter were also taken while parent animals were sacrificed and tissues obtained for biochemical and histological assessments. Results: Physical signs of toxicity were expressed in rats, significant ($p < 0.05$) decrease in Hb, % PCV, RBC, progesterone and testosterone concentrations accompanied by histological lesion on testes and ovary with subsequent decrease in litter size and weight of litters were observed. Conclusion: These results suggest adverse impact of perfloxacin on wistar rats' reproductive function.

Key words: Perfloxacin, Biochemical and Histological effects, Reproductive function

INTRODUCTION

The incidence of typhoid infection as attested to by the number of positive results of widal tests is on the increase in Africa, and the disease is most prevalent during dry season probably due to the effect of temperature on the organism (CDC, 1999).

Estimates of 17 million cases are recorded yearly and 6 million cases are fatal (WHO, 1991). Low hygiene standards which gives room for increase proliferation of the causative agent *Salmonella typhi* explains in part the incidence of the disease. Contraction of the disease is usually through ingestion of the bacterium in contaminated food/ water or as a result of direct contact with infected persons (CDC, 1999)

Complications of the disease such as diarrhea, heat failure and pneumonia often lead to death. Chemotherapy of the disease had relied on relatively low cost of drugs for single dose treatment of which chloramphenicol was used amongst others (Woodruft and Wright, 1987).

Development of bactericidal resistance to chloramphenicol, multiple sides effects and on account of it's bacteriostatic effects, instigated the search for more effective chemotherapeutics with reduced side effects. Perfloxacin was recently discovered.

Perfloxacin, a fluoroquinolone, is an analogue of nalidixic acid and a by product of chloroquine synthesis (Bryskier and Chamtot, 1995).

Perfloxacin has excellent cell penetration, rapid absorption and peak concentration between 1-2 hours. It acts by inhibiting DNA gyrase of bacteria and lysing of the cell membrane (Driliza, 1999). It has therefore been found to be effective in the therapy of typhoid infection. Despite the therapeutic benefits, concern has been expressed as to the safety of the drug during pregnancy.

There have been undocumented reports by expecting mothers of loss of pregnancy, miscarriage and insidious abortion following administration of perfloxacin even at the therapeutic dose.

Corresponding Author: Dr. M.U. Eteng, Department of Biochemistry, College of Medical Sciences, University of Calabar, Cross River State, Nigeria.

E-mail: mbeheten@yahoo.com

Telephone Number: +2348023804218

These claims have been scientifically proven and information on the safety of perfloxacin on pregnancy and lactation in women at present remains cursory. The present study was undertaken to evaluate the biochemical and histological alterations and effects of perfloxacin on reproductive function of wistar rats, in order to confirm its safety or otherwise on pregnancy.

MATERIALS AND METHODS

The Drug:

Perfloxacin injection (400 mg/5 ml) was obtained from Rabana Pharmacy, Calabar and used for the study.

Experimental Animals, Mating and Treatment Protocol:

Sixty four sexually active mature albino wistar rats of both sexes, weighing between 180-240 g obtained from the disease free stock of the animal facility of biochemistry Department, University of Calabar, Calabar, Nigeria were used for the study. Prior to experimentation, permission for the use of animals and animal protocol was obtained from the faculty of Basic Medical Science animal ethics Committee, University of Calabar.

The animals were randomly selected based on average body weight into four study groups of 16 animals (8 males, 8 females) per group.

Each male and female of a study group was housed together in a stainless cage with plastic bottom grid and wire screen top to allow for mating. Each study group had eight mating units.

The animal room was adequately ventilated and kept at room temperature and relative humidity of $29 \pm 2^\circ\text{C}$ and 40-70% respectively with 12 hours natural light/ dark cycle. Rat chow (Pfizer feeds Nigeria Ltd, Calabar, Nigeria), and water were given to the animals *ad-libitum*. Good hygiene was maintained by constant cleaning and removal of waste products of metabolism and spilled feed from cages daily.

Group I served as the control and Groups II to IV were perfloxacin treated groups. Following the housing of the males and females overnight to achieve mating, successful mating was detected after two days by inspection of the vaginal smear obtained from females for presence of spermatozoa (Wilkison and Pollard, 1994). This was designated as gestation day zero.

Perfloxacin in dose 11.43 mg/kg body weight in normal saline was administered via gavage to the animals of the test groups II-IV while control received 0.5 ml of normal saline for 14 days. Dose administration was done between the hours of 09:00 am and 10:00 am daily and the doses chosen corresponds to the therapeutic dosage in humans of 800 mg/70 kg body weight.

In test group II, both male and female animals were treated with perfloxacin. In test group III, only the mating females were treated while in test group IV only the males were treated.

The animals were checked daily to ascertain for number of dead animals. Clinical signs of overt poisoning such as hair coat, motor activity and state of faeces were also observed. Urine colour was also monitored daily. The animals were weighed at the commencement of the experiment and thereafter weekly to assess body weight gains and growth rate.

Assessment of Pregnancy Outcome and Preparation of Blood and Tissue Samples:

At the end of the gestation period, female parent animals gave birth to offspring from the various mating groups. The litter size and weight of the litter were recorded.

Parents of both perfloxacin treated groups were subjected to an overnight fast and the animals were anaesthetized in chloroform vapour and dissected. Blood samples were collected by cardiac puncture into EDTA treated sample tubes for haematological analysis and a portion into plain sample tubes from where sera were prepared by centrifugation and used for hormonal assay. Ovary and testis tissues were excised and fatty tissues removed and weighed and preserved for histological investigation.

Assay of Haematological Parameters:

Haemoglobin level was determined by the method of Crosby et al. 1954 and as modified by Pla and Fritz, 1971.

Percentage Packed Cell Volume (PVC) Was Determined Using the Haematocrit Method:

Total Red Blood Cell and White Blood Cells were estimated using the haemocytometric method where the blood cells were counted using the improved Neubauer counting chamber under an Olympus binocular electric microscope.

Table 1: Effects of Perfloracin Treatment on Body Weight Parameters of Adult Male and Female Wistar Rats

Parameters	Male		Female	
	Control	Pf Treated	Control	Pf Treatment
Initial Body weight(g)	205.29±2.18	205.00±2.20	187.55±2.66	187.24±2.12
Final Body weight (g)	230.71±0.93	210.76±1.39*	228.01±2.13	200.09±1.92*
Mean Weight Increase(%)	12.38±1.34	2.81±0.13*	21.57±0.25	6.86±0.10*
Growth Rate(g)	1.82±0.09	0.41±0.06*	2.89±0.04	0.92±0.01*

VALUE: MEAN±SEM. N=8

Pf Treated- perfloracin treated

* - Significant difference from the control at (p<0.05) level of confidence.

Assay of Progesterone and Testosterone:

Enzyme linked immunosorbent assay (ELISA) (1971) was used for assay of testosterone and progesterone concentrations. The EIA kits was supplied by syntron Bioresearch Inc. England.

Histological Analysis:

The method of Drurry and Wellington (1980) was used for the histological analysis.

Statistical Analysis:

The student's t-test was employed to compare to mean values of the test groups with the control and p< 0.05 was regarded significant.

RESULTS AND DISCUSSION

Results:

Perfloracin produced a significant (p<0.05) decrease in body weight gain and growth rate in both male and female treated animals (Table 2).

Table 2: Effects of Perfloracin Treatment on Heamatological Parameters of Adult Male and Female Wistar Rats

Parameters	Male		Female	
	Control	Pf Treated	Control	Pf Treated
Hb (g/dl)	11.41±0.88	5.36±0.31*	10.00±0.43	4.45±0.17*
WBC Count 10 ³ /mm ³	4.90±0.23	9.98±0.39*	4.90±0.22	10.03±0.37*
RBC Count 10 ⁶ /mm ³	7.55±0.39	4.40±0.20*	6.41±0.23	3.78±0.23*
PVC (%)	36.25±1.17	18.13±0.91*	32.25±1.24	15.38±0.19*

VALUE: MEAN±SEM. n=8

Pf Treated- perfloracin treated

* - Significant difference from the control at (p<0.05)level of confidence.

Table 3: Testosterone, Progesterone and Reproductive Organ Weights of Adult Male and Female Wistar Rats Following Administration of Perfloracin.

Study Group	Pf Treatment (11.43 mg/kg Body weight)	Testosterone ^b (ng/ml)	Progesterone ^b (ng/ml)	Reproductive organs weight	
				Testes(g)	Ovary (g)
I	Male control vs female control	1.24±0.04	1.63±0.03	2.34±0.12	0.40±0.02
II	Male Pf treated vs female Pf treated	0.55±0.01*	0.70±0.03*	1.20±0.09*	0.19±0.02*
III	Male non treated vs female Pf treated	1.15±0.04	0.70±0.05*	2.17±0.05	0.22±0.01*
IV	Male Pf treated vs female non treated	0.60±0.04*	1.38±0.12	1.24±0.05*	0.36±0.01

VALUE: MEAN±SEM. n=8

Pf Treated- perfloracin treated

* - Significant difference from the control at (p<0.05)level of confidence.

b: Testosterone levels were assayed only in males and progesterone only in females of each group and compared with their respective controls.

Table 4: Effect of Perfloracin Treatment on the Size of Litter (Number of Births) and Weight of Litter

Study Group	Pf Treatment (11.43 mg/kg Body weight)	Number of Births	Weight of litter (g)
I	Male control vs female control	6.38±0.45	7.14±0.31
II	Male Pf treated vs female Pf treated	1.88±0.32*	3.96±0.22*
III	Male non treated vs female Pf treated	3.13±0.32*	6.52±0.23
IV	Male Pf treated vs female non treated	5.73±0.30	5.73±0.30

VALUE: MEAN±SEM. n=8

Pf Treated- perfloracin treated

* - Significant difference from the control at (p<0.05) level of confidence.

The hematological data (Table 3) showed a significant ($p < 0.05$) reduction in Red blood cells, % Packed Cell Volume, and Hemoglobin levels in the perfloracin treated groups compared with the control groups. However, there were significant ($p < 0.05$) increase in the levels of the white blood cells in the perfloracin treated groups compared with the control group.

There were significant ($p < 0.05$) decreases in the progesterone and testosterone concentrations as well as reproductive organs (testis and ovary) weight of the male and female perfloracin treated animals compared with the control groups (Table 4).

(a) Control Testis.



(b) Experimental Testis.

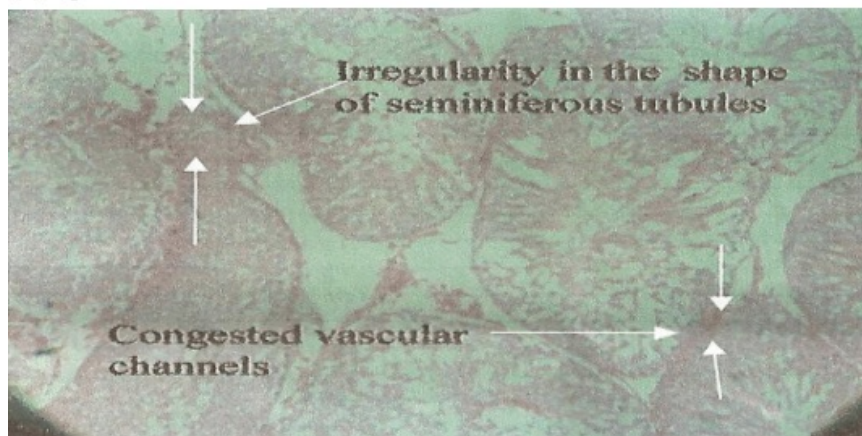


Fig. 1: Photomicrographs of rat testes. Magnification x40

- (a) Control testis showing Normal testis histology (0.5ml distilled water as placebo)
- (b) Experimental testis showing Congested Vascular channels and irregularities in seminiferous tubules after administration of perfloracin at 800 mg/kg body weight.

Perfloracin resulted in a significant decrease in litter size (number of litters) and weight of the litters.

Photomicrograph of sections of the testes showed irregularities in the shape of seminiferous tubules and congested vascular channels (Figure 1b) compared to the control whose histological architecture of the cells remained intact (Figure 1a). In the ovary tissue, the drug resulted in shrinkage of smooth muscle and dilation of fallopian tubes as seen in figure 2b compared with the control, figure 2a.

Discussion:

Following the concern expressed about the safety of perfloracin in pregnancy, the study was undertaken to evaluate the biochemical and histological alteration and effects of perfloracin on wistar rats reproductive function.

(a.) Control Ovary.



(b) Experimental Ovary

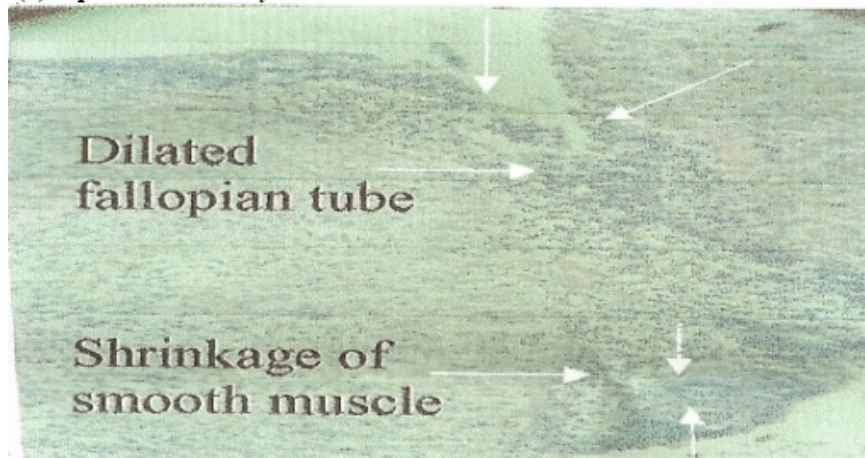


Fig. 2: Photomicrographs of rat Ovaries. Magnification x40

- (a) Control Ovary showing Normal ovary histology (0.5ml distilled water as placebo)
- (b) Experimental Ovary showing Shrinkage of smooth muscle and dilated fallopian tube after administration of perfloracin at 800mg/kg body weight.

The observed significant ($p < 0.05$) reduction in weight gain and growth rate in the perfloracin treated groups compared with the control are physical signs of toxicity as reported by Bosgue (1995) and Lovasti (1996) that physical appearance, behaviour, weight loss as well as reduced growth rate accompanying administration of xenobiotics are evidences of toxicity.

Moreover the significant reduction in the levels of Hb, RBC and %PCV in the test groups compared to the control groups was in agreement with the reports of Salako (1985). Scrinivasulu and Reddy (1995) and Umah (1996) that there were decreases in hematological parameters following animals exposure to chemicals. The plausible explanation may be that the drug may block any step in erythropoiesis. The result suggests that perfloracin administration to subjects within the reproductive age may induce anemia and availability of nutrients to tissues and organs may not be adequate as the transport medium which is the blood is decreased in volume in anemic conditions.

The observed significant increased in the levels of the WBC is in line with normal physiological response following the perception of foreign attack by the defense mechanism of the body (1996).

The significant reduction in the levels of progesterone, testosterone concentrations, ovary and testis weights in the perfloracin treated groups could be as a result of the toxicity of peerfloracin on the reproductive organs as evidenced by results of the Histopathological analysis. This is in agreement with Frank¹⁷ who reported male reproductive function distortion following exposure to fluoroquinilones and Kurkhardt¹⁹ who also reported quinolone mediated distortions of ovary with reduced progesterone level and reduced libido in women.

Fecundity parameters (number of births of litter size) and weights that were reduced by perfloracin administration were direct cumulative effects of perfloracin toxicity.

Optimum levels of progesterone amongst other factors are required to maintain pregnancy. An altered endocrine environment as well as altered structural integrity of the reproductive organs as observed in this research may lead to fetal resorption or insidious abortion. These factors might have contributed to the decrease in litter size observed.

In conclusion, perfloxacin in dose of 11.43 mg/kg body weight administered to rats for 14 days produced physical toxicity, marked decrease in Hb, %PCV, RBC as well as progesterone and testosterone concentrations with Histopathological lesions on the gonads culminating in decrease in litter size and weight of litter. On account of the observed drastic reduction in fecundity parameters arising from perfloxacin induced biochemical and histological alteration, the drug may adversely affect reproductive functions in wistar rats. We submit that caution should be exercised in the use of the drug during pregnancy and lactation as the safety margin of the drug is narrow.

REFERENCES

- Centre for Disease Control (CDC), 1999. Incidence of food born illness. Preliminary Data from the food borne active surveillance Network. (Foodnet), United MMWR, 48: 189-194.
- World Health Organisation., WHO, 1991. information Aide-memire, No 149.
- Woodruft, A.W. and S.G. Wright, 1987. A synopsis of infectious and tropical diseases.
- Bryskier, A. and J.F. Chamtot, 1995. Classification and structural activity of fluoroquinolones. *Drugs*, 49(suppl 2): 16-28.
- Driliza, K., 1999. Mechanism of fluoro quinolone action. *Curr. pin. Microbiology*, 2(5): 504-508.
- Wilkison, J.M. and I. Pollard, 1994. In uterus Exposure to caffeine causes delayed neural tube closure in rats' embryos. *Teratogenesis, carcinogenesis and metagenesis*, 14: 205-211.
- Crosby, W.H., J.L. Munn and F.W. Furth, 1954. Standardizing a method for clinical hemoglobinometry. *U S Armed Forces Med. J.*, 1954: 5:693-703
- Pla, G.W. and J.C. Fritz, 1971. Collaborative test in chicks and rats for measuring availability of iron. *Journal of Association of Analytical Chemists*, 54(1): 13-17.
- Engrall, E. And P. Perlman, 1971. Qualitative Enzyme-linked immunoassay. *immunochemistry*, 8: 871.
- Drury, R.A. and E.A. Wallington, 1980. *Histological techniques*, 5th edition, London Oxford University press. London, pp: 199-220.
- Bosque, M.A., J.L. Domingo and S. Corbellar, 1995. Assessment of the developmental toxicity of deporexamine in mice. *Arch. Toxicol*, 60: 174-183.
- Lovasti, M.R., C. Manzoni, M. Daldossi, S. Spotts and C.R. Svton, 1996. Effects of subchronic exposure of SO₂ on lipid and carbohydrate metabolism in rats. *Arch. Toxicol.*, 70: 164-173.
- Salako, I.A., 1985. International symposium on the contribution of quinolones in chemotherapy, Video tape. France.
- Screenivasulu, Y. and G.R. Reddy, 1995. Heamatological changes in Garden lizard, *Calotes versicolor*), due to the digestive secretion of the grass hopper *Poeculocurus pictus*. *Drug chem. Toxicol.*, 18: 223-229.
- Umah, I.A., J.Z. Kaladapa, E.T. Otukkonyong, J.J. Omega and L.B. Modus-Burati, 1996. Garlic induced haemolytic anaemic in garlic fed rats may be associated with decreased levels of erythrocyte reduced glutathione and serum ascorbic acid. *West African Journal of Biological Sciences.*, 4: 73-81
- Guyton, A.C. and Hall J.E., 1996. *Textbook of medical physiology*. Philadelphia: W.B, Saunders Company.
- Frank, S., 1981. Male reproductive endocrinology. *Clin. Obst. Gynec.*, 8: 549-569.
- Kurkhardt, J.E., 1990. Histological and Histochemical changes in articular cartilages of immature beagle dogs dosed with digloxacin, a fluoroquinolone. *Journal of Vet. Pathology*, 27: 162-167.