

Anaesthesia in Paediatric Patients Undergoing Bronchoscopy: Comparison Between Dexmedetomidine/propofol, and Midazolam/propofol

¹Mostafa El-Hamamsy, ¹Saied Sadek., ²Abd-Elrahman Ahmed Ahmed and
²Mohamed Abd-Elrahman Salem.

¹Anaesthesia Dept., Faculty of Medicine, El-Fayum Univ., Egypt.
²Anaesthesia Dept., Faculty of Medicine, Al-Mounofia Univ., Egypt.

Abstract: Paediatric bronchoscopy requires a deep level of anaesthesia of relatively short duration. This prospective randomized study compared the effectiveness of a low-dose infusion of propofol in combination with either dexmedetomidine, or midazolam for intravenous anaesthesia in paediatric patients undergoing bronchoscopy. Sixty paediatric patients, ASA I-II boys and girls, aged 2-10 yr and body weight between 12–30 kg, undergoing elective rigid bronchoscopy for removal of airway foreign bodies were studied. Patients were allocated into 2 groups: Group (D/P) received dexmedetomidine with propofol infusion, and Group (M/P) received midazolam with propofol infusion. There were no significant differences between the two groups as regards demographic characteristics, and haemodynamic data. It was noticed that time to full recovery was significantly more rapid in the dexmedetomidine/propofol group. No postoperative complications were reported. It was concluded that dexmedetomidine in combination with propofol anaesthesia is a safe, practical alternative for paediatric patients undergoing bronchoscopy and may be preferable to midazolam/propofol, because of the significantly shorter recovery time.

Key words: Dexmedetomidine; Midazolam; Propofol; Paediatric Bronchoscopy.

INTRODUCTION

Rigid and fibroptic bronchoscopy are brief but intensely stimulating procedures and present a challenge for anaesthetic management (Pinzoni *et al.*, 2007). In infants and children, removal of airway foreign body is performed under general anesthesia and through a ventilating rigid bronchoscope (Soodan *et al.*, 2004).

Early diagnosis and bronchoscopic removal of the foreign body would protect the child from serious morbidity and even mortality. The small paediatric airway is frequently shared for anaesthesia and endoscopy. Complete cooperation and good communication between the endoscopist and the anaesthetist is paramount in achieving an optimal outcome (H K Tan *et al.*, 2000).

Systemic arterial desaturation occurs during bronchoscopy, and may be caused by several factors, including topical anaesthesia, sedation, partial airway obstruction, abnormal distribution of ventilation and reflex response to bronchoscopy and lavage. If desaturation persists after the end of the procedure, this is most likely to result from oversedation, as the other factors produce only transient changes (Faarrell, 2004).

Anaesthetic goals in management of patients undergoing bronchoscopy include: adequate depth of anaesthesia with minimal airway secretions, stable haemodynamics and a rapid recovery of airway reflexes at the end of the procedure. Persistence of sedation beyond the end of the procedure is undesirable, as this may result in detention of the patient in hospital (Crawford *et al.*, 1993).

Dexmedetomidine is a potent and highly selective α_2 -adrenoreceptor agonist. It has sedative-hypnotic, anxiolytic, and analgesic, anaesthetic-reducing and sympatholytic effects. In contrast to other agents, the sedation and analgesia produced by dexmedetomidine are achieved without significant respiratory or haemodynamic compromise. In addition, patients sedated with this agent are well oriented, easily rousable and can respond to instructions from the medical staff (Tobias and Berkenbosch, 2002).

Recently, dexmedetomidine and a small dose of propofol were used successfully to sedate a critically ill infant for MRI (Young, 2005), and many other paediatric procedures (Ramsay and Luterman, 2004) and (Ebert and Maze, 2004).

Propofol is a substituted phenol (diisopropylphenols) anaesthetic that is associated with smooth induction,

Corresponding Author: Mostafa El-Hamamsy, Anaesthesia Dept., Faculty of Medicine, El-Fayum University, Egypt.
E-mail: mostafah30@hotmail.com

and rapid recovery from anaesthesia. Its safety and efficacy in paediatric patients have been demonstrated in numerous studies.

Reported side effects of propofol include pain on injection into small veins (which may be prevented by pretreatment with small doses of intravenous lidocaine), respiratory depression, airway obstruction and dose-related decreases in blood pressure and cardiac output (Saint-Maurice *et al.*, 1989).

It has been shown that propofol have synergistic hypnotic effects when used in conjunction with other classes of analgesic/sedative agents as barbiturates, benzodiazepines, opioids, and ketamine (Kogan *et al.*, 2003). Because it is a poor analgesic, propofol usually requires the use of an adjunctive analgesic agent e.g. Fentanyl (Pepperman and Macrae, 1997).

Midazolam, the only clinically available water soluble benzodiazepine, has an analgesic action by its action on the benzodiazepine (gamma -aminobutyric acid A) GABAA receptor complex that is present in the spinal cord, and is involved in nociceptive mechanisms (Crevat-Pisano *et al.*, 1986).

The aim of this clinical study was to analyze and compare the effectiveness of a low-dose infusion of propofol in combination with either Dexmedetomidine, or Midazolam for intravenous anaesthesia in paediatric patients undergoing bronchoscopy. These two methods were compared in terms of sedation and anxiolysis, haemodynamic stability, oxygen saturation, and operator acceptability. Time to recovery and time to discharge from post anaesthesia care where also considered.

Patients and Methods:

After institutional approval and a written informed consent was obtained from parents, 60 ASA I-II boys and girls, aged 2-10 yr and body weight between 12–30 kg, undergoing elective rigid bronchoscopy for removal of airway foreign bodies over a period of 2 years and 6 months in our hospital was included in this study. Exclusion criteria were unusual response to the studied anaesthetic agents, patients who were currently receiving, or had recently taken, a benzodiazepine, and significant cardiovascular, pulmonary, hepatic, renal or muscular disease.

During the preoperative visit, consent was obtained; weight and oxygen saturation were recorded. According to hospital policy, all patients were fasting for at least 2 hours before the procedure, and they arrived in the operating room with an intravenous cannula in situ.

On arrival in the operating room, and prior to induction of anaesthesia, all patients were connected to slandered monitors that included five leads electrocardiogram (ECG), and ECG leads II and V5 were continuously monitored, a noninvasive arterial pressure (Dinamap, Criticon, CA, USA), and a digital pulse oxymetry (Novamatrix, 515C, NY, USA). Heart rate (HR), mean arterial blood pressure (MAP), and digital oxygen saturation (SpO₂) were recorded every 5 min for the duration of the study. After the measurement of baseline HR, MAP, and SpO₂, all patients received atropine 0.01 mg/kg IV.

For intraoperative somnolence, all patients received a propofol bolus of 1mg/kg (Propofol 1%, Fresenius Kabi- Deutschland) over a 10-minute period followed by a propofol infusion between 25-100µg/kg/min. To decrease the likelihood of pain on injection, the propofol emulsion was diluted 1:1 with 5% dextrose solution, and the induction dose was preceded by intravenous lidocaine (0.1 ml/kg of a 0.1% solution).

Each patient received 10% topical nebulized lignocaine puffs, to each nostril and to the oropharynx. Further increments of 10% nebulized lignocaine were administered via the bronchoscope by the operator as required. All bronchoscopies were performed with the patient in a semi-recumbent position. Oxygen was administered by face mask if oxygen saturation decreased to less than 85%. Introduction of bronchoscope was facilitated by suxamethonium 1 mg/ kg, and the children were maintained on intermittent positive pressure ventilation (IPPV) with O₂ through a 'T' piece connected to the side arm of the rigid bronchoscope (Storz, Germany), and intermittent doses of suxamethonium.

For intraoperative sedation and analgesia, a sealed envelope was opened to allocate patients randomly to one of two groups (n=30) as follow:

I: Group (D/P): Received dexmedetomidine (Precedex®, 100µg/ml, Abbott Laboratories, North Chicago-USA) bolus of 1µg/kg over a 5-minute period followed by a dexmedetomidine infusion between 0.25-0.75µg/kg/hr.

II: Group (M/P): Received midazolam (Dormicum® Roche, Hoffmann-La Roche Ltd. Basel, Switzerland) 0.1mg/kg over a 5-minute period, followed by a midazolam infusion between 0.1- 0.2mg/kg/hr until adequate sedation was achieved.

Ramsay scale for sedation (Ramsay *et al.*, 1974) (Table 1) was used to assess the onset of a good level of sedation (score of 4-5), at which the procedure can be started.

Depth of anesthesia and bronchoscopy conditions was assessed clinically by haemodynamic parameters (heart rate, blood pressure), lacrimation, sweating, coughing or bucking and movement. In all cases, if the patient had marked or moderate response to the procedure (any distress, movement or coughing), the additional medications were bolus dose of propofol 0.5 mg/kg given IV via pump over 30 sec., and the infusion rate of propofol and the study sedative drug was increased by 50%. When more than 10 boluses of propofol were used, propofol infusion was increased up to a maximum of 100µg/kg/min. At the end of the procedure, total doses of the study sedative drug and total dose of propofol were calculated. The patients were observed for the cardiorespiratory effects of propofol, and any changes in HR, MAP, or SpO₂ (from the baseline value) were recorded.

A change of 20% in the value of heart rate, systolic and diastolic blood pressures from the basal value was taken as a significant change. Arterial desaturation was defined as SpO₂ value less than 90%. Anaesthetic drug infusions were discontinued when bronchoscopy had been completed and the duration of the procedure, total doses of propofol, total doses of study drugs, and duration of anaesthesia were recorded. Lidocaine 1.5 mg/kg was given intravenously to all patients at the end of the procedure to decrease the incidence of coughing in the postbronchoscopy period.

Evaluation of the bronchoscopy conditions by the bronchoscopist and anaesthesiologist during the procedure were recorded. Any untoward effects (e.g. cough, laryngeal spasm, breath-holding or excitement) were recorded. Postoperatively, the children were nursed with humidified oxygen, and monitoring was continued until 1h after the end of the procedure or as long as such care was needed.

Postanaesthesia recovery scores, modified from Steward (Steward, 1975) (Table 2), were determined by an independent blinded observer at 10-min intervals from the time the infusion was stopped until discharge from the recovery room. Time spent in the recovery area was also noted (Time to discharge).

Patients were regarded as ready to be discharged from the recovery room when they are fully awake and communicated normally.

Statistical Analysis:

The results were reported as mean values ± standard deviations (SD). Nominal data were compared between the three groups by using chi-square test. Haemodynamics and recovery data were analyzed with repeated-measures analysis of variance (ANOVA) to compare changes within each group and a two-tailed unpaired Student's t test was used for patient characteristics Student's t-test to compare different group data. $P < 0.05$ was accepted as statistically significant.

RESULTS AND DISCUSSION

Results:

As regards the demographic characteristics, there were no differences in the mean age, height, or weight of patients, sex distribution, and ASA physical status, baseline SpO₂ duration of bronchoscopy, and duration of general anaesthesia among the two groups as seen in Table (3). All patients completed the study protocol, and during bronchoscopy, minimal or moderate response was observed in 3 patients in midazolam group, and 2 patients in dexmedetomidine group. Additional doses of propofol were required almost equally in both groups with no statistically significant difference ($P > 0.05$) (Table 4).

According to body weight, duration of bronchoscopy, and number of additional doses of sedative drug, the total doses of propofol throughout the procedure, total doses of propofol per kilogram body weight, total dose of the study drug throughout the procedure, total dose of the study drug per kilogram body weight are presented in (Table 4). As regard haemodynamic data, there were no clinically significant changes in HR (Figure 1) or MAP (Figure 2) over time or between groups. However, the number of patients experiencing MAP decreases $> 10\%$ (compared to baseline) during induction was higher in midazolam group. During the procedure, several patients in midazolam group had episodes of increased HR and MAP, but the frequency of these was not significantly different between the two groups ($P > 0.05$), and no interventions were required to treat changes in HR or MAP.

During administration of medication, SpO₂ had a small decrease in several patients in both groups. However, there were no arterial desaturation $> 10\%$ in either group (Fig. 3). Acceptability of the bronchoscopy conditions to the bronchoscopist and anaesthesiologist was high in both groups during the procedure. There were no episodes of apnea, airway obstruction, or emesis in any patient, and no postoperative complications were reported in any patient in both groups.

Using recovery scoring system modified from Steward, it was noticed that time to full recovery was significantly more rapid in the D/P group. The individual Steward scores for complete recovery of consciousness, airway reflexes, and motor function were achieved significantly more rapidly in the D/P group compared with M/P group (Table 5).

Table 1: Ramsay Scale for Sedation [14].

Score	Level of sedation achieved
1	Patient anxious, agitated or restless.
2	Patient co-operative oriented and tranquil.
3	Patient responds to commands.
4	Asleep but with brisk response to light glabellar tap or loud auditory stimulus.
5	Asleep, sluggish response to light glabellar tap or loud auditory stimulus.
6	Asleep, no response.

Table 2: Recovery Scoring System Modified from Steward [15]:

<i>Consciousness:</i>	
Awake	3
Responds to verbal stimuli	2
Responds to tactile stimuli	1
Not responding	0
<i>Airway:</i>	
Cough on command or cry	2
Maintains good airway	1
Require airway assistance	0
<i>Motor:</i>	
Moves limbs purposefully	2
Nonpurposeful movements	1
Not moving	0

Table 3: Demographic data of the two groups (mean ± SD).

Parameter	Group D/P (n=30)	Group M/P (n=30)	P value
Age (yr)	5.8 ± 2.9	5.4 ± 3.2	>0.05
Weight (kg)	16.8 ± 7.4	17.5 ± 6.6	>0.05
Male/female	16/14	15/15	>0.05
ASA class I/ II	18/12	17/13	>0.05
Baseline SpO ₂	87 ± 12	88 ± 11	>0.05
Duration of bronchoscopy (min)	29 ± 11	31 ± 12	>0.05
Duration of general anaesthesia (min)	51 ± 13	53 ± 11	>0.05

No significant difference between the two groups.

D= Dexmedetomidine, P= Propofol, M=Midazolam, SpO₂= oxygen saturation.

Table 4: Doses of drugs used in the two groups (mean ± SD).

Parameter	Group D/P (n=30)	Group M/P (n=30)	P value
Total dose of propofol (mg)	138±35	134±57	>0.05
Total dose of propofol /kg (mg)	7.4±3.7	7.8±2.9	>0.05
Total dose of study drug	32±1.3 (µg)	4.5±1.8(mg)	-
Total dose of study drug /kg	1.8±0.4(µg)	0.3±0.6(mg)	-

No significant difference between the two groups.

D= Dexmedetomidine, P= Propofol, M=Midazolam.

Table 5: Data of Recovery in all groups (mean ± SD).

Parameter	Group D/P (n=30)	Group M/P (n=30)	P value
Time to full consciousness (min)	78±12*	96±14	< 0.05
Time to discharge.	101±8*	128±13	< 0.05

* Significantly lower than the other group (P < 0.05).

D= Dexmedetomidine, P= Propofol, M=Midazolam.

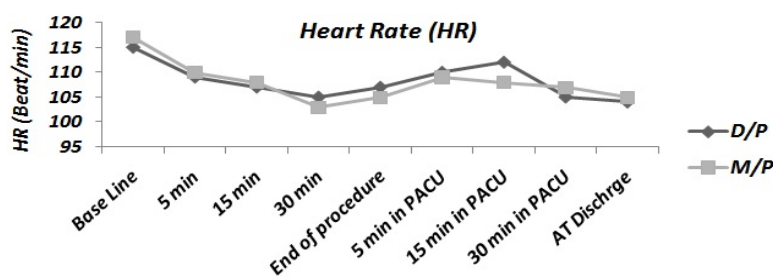


Fig. 1: Heart Rate changes in the two groups
No significant difference between the two groups.
D= Dexmedetomidine, P= Propofol, M=Midazolam.

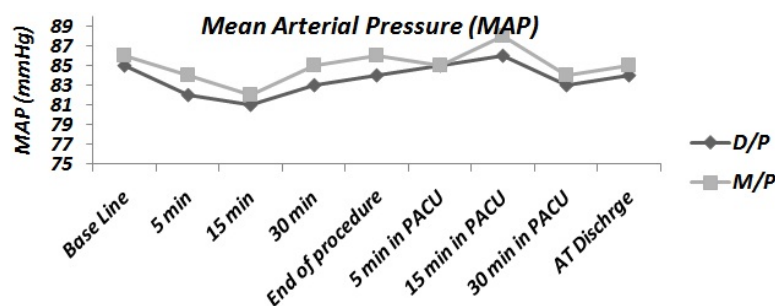


Fig. 2: Mean Arterial Pressure (MAP) changes in the two groups.
No significant difference between the two groups.
D= Dexmedetomidine, P= Propofol, M=Midazolam.

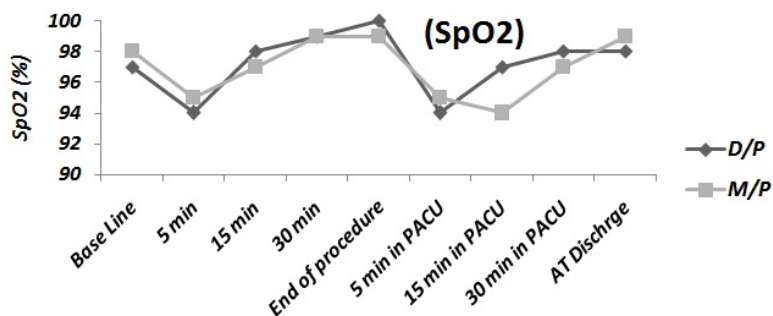


Fig. 3: Oxygen Saturation (SpO2) changes in the two groups.
No significant difference between the two groups.
D= Dexmedetomidine, P= Propofol, M=Midazolam.

Discussion

Aspiration of a foreign body may be a life-threatening emergency in children requiring immediate bronchoscopy under general anesthesia. Early diagnosis and bronchoscopic removal of the foreign body would protect the child from serious morbidity and even mortality. In infants and children, removal of airway foreign body is performed under general anesthesia and through a ventilating rigid bronchoscope. Anesthesia for rigid bronchoscopy is a challenging procedure for the anesthesiologist who must share the airway with the bronchoscopist and maintain adequate depth of anesthesia.

General anesthesia in these cases can be maintained by either inhalational agent or total intravenous technique. During induction of anesthesia, spontaneous respiration is safer than the apnea technique with complete neuromuscular paralysis. Positive pressure ventilation may drive the foreign body further peripherally (Holinger, 1994). As anaesthesia is deepened, special care should be taken to preserve spontaneous ventilation, at least until the nature and location of the foreign body have been determined by bronchoscopic examination.

Coughing, occurring if anaesthesia lightens may help move the foreign body towards the bronchoscope, but at the same time may make it more difficult for the endoscopist to grasp the object. The endoscopist should first expose the larynx in case the foreign body is present in the larynx or hypopharynx (Matot et al., 2000).

The bronchoscope is then inserted and the tracheobronchial tree is inspected while the patient is anesthetized and has his spontaneous breaths assisted through the bronchoscope side arm. At this point, if the patient coughs, a small increment of propofol or fentanyl may be administered. During rigid bronchoscopy it is often difficult to maintain adequate ventilation and oxygenation in these patients as pulmonary gas exchange is already deranged. If bradycardia is encountered or there is any evidence of hypoxia, priority for management must be given to the anesthetist and adequate ventilation established (H K Tan et al., 2000). It is difficult to maintain an adequate depth of anesthesia during the procedure, as there is a constant leak of anesthetic gases through the proximal end and around the bronchoscope (Soodan et al., 2004).

In this study, total intravenous anesthesia technique was chosen to compare the effectiveness of a low-dose infusion of propofol in combination with either dexmedetomidine, or midazolam. Bronchoscopic procedures are associated with prolonged manipulation of the upper respiratory tract, with subsequent sympathetic responses which include hypertension, tachycardia, and tachyarrhythmias, and are associated with an acute increase in plasma concentrations of epinephrine and norepinephrine. It was hypothesized that α_2 -agonists can modulate the sympathetic response during these procedures. Previous studies reported that premedication with oral clonidine (4-4.5 mg/kg) attenuates hemodynamic responses to bronchoscopy (Matot et al., 2000).

Dexmedetomidine being a potent and highly selective α_2 -adrenoreceptor agonist was used in this study in a dose of 1 μ g/kg over a 5-minute period followed by infusion between 0.25-0.75 μ g/kg/hr, and it was proved to produce good level of sedation with maintenance of hemodynamic stability and rapid recovery and faster rate of discharge from PACU when compared with midazolam (Table 5).

Recently, dexmedetomidine was used for sedation in bronchoscopic procedures by many investigators with the conclusion that dexmedetomidine in patients at high risk for respiratory complications demonstrates efficacy, hypertension and tachycardia normally caused by bronchoscopy were not observed, and known side-effects of dexmedetomidine were not problematic (Abouzgheib et al., 2007). Also, dexmedetomidine was used in combination with propofol during laryngoscopy and bronchoscopy in two complicated pediatric patients and in these two cases dexmedetomidine provided sedation for at least 2 hours after the termination of the infusion, and neither patient required additional sedative or analgesic medications in the immediate post-operative period, and it was concluded that with its potent analgesic, sedative, anxiolytic and anti-sialogogue properties, dexmedetomidine may be a useful agent for brief airway procedures in children (Seybold et al., 2007).

Propofol and midazolam may cause hypotension, when given as a bolus or by infusion to produce sedation and anaesthesia. However, both drugs have been shown to be devoid of cardiorespiratory side effects when used in small doses to provide sedation (Crawford et al., 1993). In this study, both drugs had no adverse effects on systemic pressure. Also, both propofol and midazolam may produce respiratory depression. In this study, equal numbers of patients in each group suffered arterial desaturation as a result of sedation alone, before the effect of the bronchoscope and washing solutions. However, median least oxygen saturation recorded during the procedure was smaller in the dexmedetomidine group than in the midazolam group, although this was not statistically significant.

Previous studies have demonstrated that, if used cautiously and if dosage is titrated to effect, it is possible to use midazolam alone for sedation in fibroptic bronchoscopy, without detriment to oxygen saturation after the end of the procedure. However, its effects on memory and motor performance make it, less suitable for use in the outpatient (Crawford et al., 1993).

In a major review of sedation for fibroptic bronchoscopy, the authors stated: "no single agent provides amnesia, anxiolysis and analgesia, so a combination of drugs is necessary" (Shelley et al., 1989).

In this study, it was considered that an infusion of propofol, after topical lignocaine anesthesia, provides conditions which come close to this ideal. In addition, the rapid onset and short duration of action of propofol allow rapid changes in depth of sedation and fast recovery without the need for expensive antagonist agents.

Conclusion:

It was concluded that sedation and analgesia produced by dexmedetomidine are achieved without significant respiratory or haemodynamic compromise. In addition, patients sedated with dexmedetomidine are well oriented, easily rousable, and this may make this agent to be most appropriate drug for use in the "high-risk" patient, in who ease of change of depth of sedation; rapid recovery and cardiovascular stability are essential requirements.

Study limitations: The relatively small sample size of this study may limit the interpretation of these results. However, the results of the present study should encourage the use of dexmedetomidine for paediatric patients undergoing bronchoscopic procedures.

REFERENCES

- Arom, K. and R. Emery, 1992. Coronary sinus cardioplegia: clinical trial with only retrograde approach. *Ann. Thorac. Surg.*, 53: 965-971.
- Abouzgheib, W., J. Littman, M. Pratter, T. Bartter, 2007. Efficacy and safety of dexmedetomidine during bronchoscopy in patients with moderate to severe COPD or emphysema. *Journal of Bronchology*, 14: 233-236.
- Crawford, M., J. Pollock, K. Anderson, R.J. Glavin, *et al.*, 1993. Comparison of midazolam with propofol for sedation in outpatient bronchoscopy. *Br. J. Anaesth.*, 70: 419-22.
- Crevat-Pisano, P., S. Dragna, C. Granthil, P. Coassolo, J.P. Cano, G. Francois, 1986. Plasma concentrations and pharmacokinetics of midazolam during anesthesia. *J. Pharm. Pharmacol.*, 38: 578-82.
- Ebert, T., M. Maze, 2004. Dexmedetomidine: another arrow for the clinician's quiver. *Anesthesiology*, 101(3): 568-70.
- Faarrell, P.T., 2004. Rigid bronchoscopy for foreign body removal: anaesthesia and ventilation. *Paediatr Anaesth.*, 14(1): 84-9.
- Tan, H.K., S.S. Tan, 2000. Inhaled Foreign Bodies in Children - Anaesthetic Considerations. *Singapore Med J.*, 41(10): 506-510.
- Holinger, L.D., 1994. Ventilating trachea resectoscope. *Ann Otolaryngology*, 103(9): 676-8.
- Kogan, A., R. Efrat, J. Katz, B.A. Vidne, 2003. Propofol-ketamine mixture for anaesthesia in paediatric patients undergoing cardiac catheterization. *J. Cardiothorac Vasc. Anesth.*, 17(6): 691-3.
- Matot, I., J.Y. Sichel, V. Yofe, Y. Gozal, 2000. The Effect of Clonidine Premedication on Hemodynamic Responses to Microlaryngoscopy and Rigid Bronchoscopy. *Anesth Analg.*, 91:828-33.
- Pepperman, M.L., D. Macrae, 1997. A comparison of propofol and other sedative use in paediatric intensive care in the UK. *Paediatr Anaesth.*, 7: 143 -15.
- Pinzoni, F., C. Boniotti, S.M. Molinaro, A. Baraldi, M. Berlucchi, 2007. Inhaled foreign bodies in pediatric patients: review of personal experience. *Int. J. Pediatr. Otorhinolaryngol.*, 71(12): 1897-903.
- Ramsay, M.A., D.L. Luterman, 2004. Dexmedetomidine as a total intravenous anesthetic agent. *Anesthesiology*, 101(3): 787-90.
- Ramsay, M., T. Savege, B. Simpson, *et al.*, 1974. Controlled sedation with alphaxalone- alphadolone. *BMJ.*, 2: 656 -9.
- Saint-Maurice, C., I.D. Cockshott, E.J. Douglas, M.O. Richard, J.L. Harmey, 1989. Pharmacokinetics of propofol in young children after a single dose. *Br. J. Anaesth.*, 63: 667-70.
- Seybold, J.L., R.J. Ramamurthi, G.B. Hammer, 2007. The use of dexmedetomidine during laryngoscopy, bronchoscopy, and tracheal extubation following tracheal reconstruction. *Paediatr Anaesth.*, 17(12): 1212-4.
- Shelley, M.P., P. Wilson, J. Norman, 1989. Sedation for fibroptic bronchoscopy. *Thorax*, 44: 769-775.
- Soodan, A., D. Pawar, R. Subramaniam, 2004. Anesthesia for removal of inhaled foreign bodies in children. *Paediatr Anaesth.*, 14(11): 947-52.
- Steward, D.J., 1975. A simplified scoring system for the post-operative recovery room. *Can. Anaesth. Soc. J.*, 22: 111-3.
- Tobias, J.D., J.W. Berkenbosch, 2002. Initial experience with dexmedetomidine in paediatric-aged patients. *Paediatr Anaesth.*, 12(2): 171-5.
- Young, E.T., 2005. Dexmedetomidine sedation in a paediatric cardiac patient scheduled for MRI. *Can. J. Anaesth.*, 52(7): 730-2.