

Subconjunctival Anti VEGF for Conjunctival Intraepithelial and Invasive Neoplasia

Ahmed Atef Zaki, M.D., Hisham Fouad, M.D., Sherif Emera, M.D., Hany Labib, M.D.

Cornea and Ocular Surface Unit, Department of Ophthalmology, Research Institute of Ophthalmology, 2 Al Ahram Road, Giza, Egypt.

Abstract: Purpose: To evaluate the efficacy of bevacizumab as an antiangiogenic and anti lymphangiogenic agent in the management of cases with primary conjunctival intraepithelial and invasive neoplasia. **Methods:** 10 eyes of 10 patients, 7 males and 3 females with a mean age of 45 years with primary conjunctival intraepithelial and invasive neoplasia who presented with elevated vascularized swelling of the bulbar conjunctiva participated in this study. A diagnosis of conjunctival neoplasia was made by surgical biopsy. An immunohistochemical study of VEGF in all conjunctival specimens was done and the expression pattern of the VEGF was studied. All subjects were injected with a single subconjunctival 2.5 mg. (0.1 ml) bevacizumab and morphological changes of the neoplasm were observed and followed up for 12 months. Impression cytology was done to all eyes at the end of the follow up period at the site of the conjunctival lesion to detect any abnormal tumor cells. **Results:** Immunohistochemical study of VEGF in the conjunctival specimens showed a strong immunoreactivity in the expression pattern of VEGF in 7 out of the 10 conjunctival specimens. Dramatic recession of the size of the neoplasm and the feeding vasculature was observed two weeks after injection in 6 eyes. This decrease continued noticeably for one month and plateaued after that. Five eyes had total cure with no recurrence at the end of the 12 month follow up period, as proven by impression cytology to the conjunctiva at the site of the lesion, 3 eyes had decrease in the size and vascularity with no evidence of tumor cells in the impression cytology. The remaining 2 eyes had recurrences at the end of the 12 months follow up period. **Conclusion:** Subconjunctival bevacizumab as an antiangiogenic and anti lymphangiogenic agent is effective in managing highly vascular neoplasms of the conjunctiva as conjunctival intraepithelial and invasive neoplasia.

Key words: Bevacizumab, Avastin, VEGF, conjunctival intraepithelial neoplasia

INTRODUCTION

Angiogenesis has been defined as the formation of new blood vessels from preexisting vascular structures. Corneal neovascularization (NV) occurs when the balance between angiogenic and antiangiogenic factors shifts toward angiogenic factors. Vascular endothelial growth factor (VEGF) has been found to be a significant angiogenic factor in corneal NV in human and animal models. Therapy specifically aimed at anti- VEGF may suppress corneal NV and increase the chance of transplant survival (DeStafeno and Kim, 2007). Inhibition of VEGF and, thereby, inhibiting angiogenesis can be an effective treatment for a variety of ocular diseases followed by neovascularization such as proliferative diabetic retinopathy and corneal neovascularization (Manzano et al. 2006, Hosseini and Nejabat 2007).

Bevacizumab (Avastin[®]), a humanized monoclonal anti-body to VEGF, was designed for intravenous application and was approved for the treatment of colorectal cancer (Kabbnavari *et al.*, 2003, Emmanouilides *et al.*, 2004, Hurwitz *et al.*, 2004). Recently bevacizumab has been used, with promising results, as a systemic or intra-vitreous treatment for exudative age-related macular degeneration (AMD) (Michels *et al.*, 2005, Avery *et al.*, 2006).

The diagnosis of squamous conjunctival neoplasia is typically made by biopsy. Like most squamous epithelial tumors, invasion beneath the epithelium into the substantia propria defines these lesions as carcinoma. When the tumor is contained within the epithelium, it does not have access to the lymphatic system (metastatic potential). Management of these cases includes surgical excision with cryotherapy and/or alcohol application

Corresponding Author: Ahmed Atef Zaki, M.D., Cornea and Ocular Surface Unit, Department of Ophthalmology, Research Institute of Ophthalmology, 2 Al Ahram Road, Giza, Egypt. 27 Road 265, New Maadi, Cairo, Egypt. Tel.: (20) 122421415.
E-mail: ahmedazaki@hotmail.com

(Finger 2008), and use of topical chemotherapy with mitomycin C (Daniell *et al.* 2002, Shields *et al.* 2002, Prabhasawat *et al.* 2005), 5-fluorouracil, or interferon (Boehm and Huang 2004, Holcombe and Lee 2006).

The subconjunctival injection is a widely used delivery method of drugs in the eye. It seems to be a good option to inhibit corneal neovascularization. This delivery method has the advantage of being easy and simple to perform, and has minimal related complications. The possible systemic absorption and extra ocular side effects need to be adequately addressed to avoid potential complications (Barros and Belfort, 2007).

The aim of this study is to evaluate the effect of a single subconjunctival bevacizumab injection in primary conjunctival intraepithelial and invasive neoplasia with accompanying neovascularization and estimate the rate of recurrence over a 12 month period.

MATERIALS AND METHODS

Ten eyes of 10 patients, 7 males and 3 females (mean age 45 years) with primary conjunctival intraepithelial neoplasia who presented with elevated vascularized swelling of the bulbar conjunctiva participated in this study. The cases were collected from the outpatient clinics of the Research Institute of Ophthalmology in Giza, Egypt. The study adheres to the provisions of the Declaration of Helsinki for research involving human subjects and all subjects signed an informed consent form before participation in the study.

A diagnosis of conjunctival intraepithelial and invasive neoplasia was made by surgical biopsy and histopathology of all specimens. An immunohistochemical study of VEGF in all conjunctival specimens was done and the expression pattern of the VEGF was studied. A single subconjunctival injection of bevacizumab (Avastin; Genentech, Inc., South San Francisco, CA, USA) 2.5 mg. (0.1 ml) was given to all eyes at the outpatient clinics. The injection site was the upper temporal bulbar conjunctiva regardless the site of the lesion. Morphological changes of the neoplasm were observed and followed up every month for 12 months using slit lamp biomicroscopy. Impression cytology was done to all eyes at the end of the follow up period at the site of the conjunctival lesion to detect any abnormal tumor cells.

RESULTS AND DISCUSSIONS

Results: Immunohistochemical study of VEGF in the conjunctival specimens showed a strong immunoreactivity in the expression pattern of VEGF in 7 out of the 10 specimens. Histopathologic study was done for all 10 specimens and showed positivity for conjunctival intraepithelial neoplasia in 8 specimens and invasive neoplasia of the conjunctiva in 2 specimens.

Out of the 10 eyes, dramatic recession of the size of the neoplasm and the feeding vasculature was observed in 6 eyes two weeks after injection. These 6 eyes were among the 7 specimens showing high immunoreactivity in the expression pattern of VEGF. The remaining 4 eyes, showed a slight decrease in the size of the neoplasm and feeding vasculature one month after injection. Figure 1 shows conjunctival neoplasia pre and one month post subconjunctival bevacizumab injection. This decrease continued noticeably for two months and either plateaued or showed minimal changes after that in all 10 eyes.

At the end of the 12 month follow up period, 5 eyes had total cure with no recurrence, as proven by impression cytology done to the conjunctiva at the site of the lesion, 3 eyes had a decrease in the size and vascularity with no evidence of tumor cells in the impression cytology. The remaining 2 eyes had recurrences at the end of the 12 months follow up. The 2 recurrent cases were among those showing low immunoreactivity in VEGF expression. One of these recurrent cases suffered from invasive neoplasia of the conjunctiva.

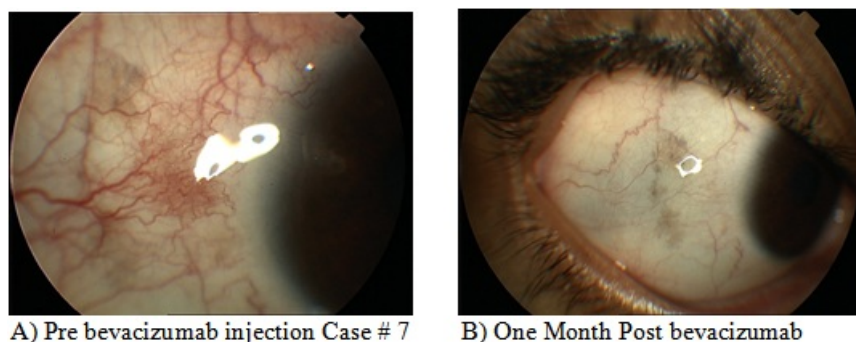


Fig. 1: Conjunctival neoplasia pre and one month post subconjunctival bevacizumab injection. in case # 7.

Discussion:

In this study, subconjunctival bevacizumab, an antiangiogenic and antilymphangiogenic agent, has proven to be an effective tool in managing vascular neoplasms of the conjunctiva as conjunctival intraepithelial neoplasia. We found that the use of subconjunctival bevacizumab gave a dramatic recession of the size of the neoplasm and the feeding vasculature in 6 out of 10 eyes two weeks after injection. The remaining 4 eyes also showed a slight decrease in the size and the vasculature one month after injection. This decrease continued noticeably for two months and plateaued or had minimal changes after that in all the 10 eyes. At the end of the 12 month follow up period, 5 eyes had a total cure with no recurrence as proven by impression cytology to the conjunctiva at the site of the lesion, 3 eyes had a decrease in the size of the neoplasm and feeding vascularity with no evidence of tumor cells in the impression cytology. The remaining 2 eyes had recurrences at the end of the 12 months follow up. The 2 recurrent cases were among those showing low immunoreactivity in VEGF expression possibly due to the difference in the nature of the lesion vascularity thus did not show high response to bevacizumab. We noticed that bevacizumab was more effective in highly vascularized neoplasms with small-sized, cork-screw shaped vessels. One of these recurrent cases suffered from invasive neoplasia of the conjunctiva.

Vascular endothelial growth factor (VEGF) is a potent angiogenic factor acting on VEGF receptor-1 (Flt-1) and VEGF receptor-2 (KDR, Flk-1). Inhibition of VEGF has been shown to prevent tumor growth (Kim *et al.* 1993). The expression of VEGF is elevated by diverse stimuli, which include proto-oncogene activation and hypoxia (Dibbens *et al.* 1999).

Angiogenesis, the growth of new vessels from preexisting vessels, is a fundamental step in tumor growth and progression. Vascular endothelial growth factor (VEGF) is a key angiogenic factor implicated in tumor blood vessel formation and permeability. Overexpression of VEGF has been observed in a variety of cancers and has been associated with a worse relapse-free and overall survival. The antiangiogenic agent bevacizumab, a monoclonal antibody directed against VEGF, has shown clinical benefit in multiple cancers like metastatic colorectal, lung, and breast cancer used in combination with chemotherapy a multitude of clinical trials combining bevacizumab with a variety of chemotherapy agents as MMC. Against this background, several preclinical studies have investigated the antitumor activity of combined anti-HER1/EGFR and anti-VEGF agents (Herbst *et al.* 2003). Additional trials are under way evaluating the feasibility of bevacizumab in combination with chemotherapy in treating conjunctival neoplasia. (Hurwitz *et al.* 2004, Kabbinarvar *et al.* 2003, Kabbinarvar *et al.* 2005, Miller *et al.* 2005, Johnson *et al.* 2005, Sandler 2007)

Bevacizumab has a good potential for use in managing highly vascular neoplasms of the conjunctiva as conjunctival intraepithelial and invasive neoplasia. Further studies are needed on a larger number of patients and possibly combining bevacizumab with other treatment modalities to increase the success rate and prevent recurrence of these highly resistant, fast recurring neoplasms.

REFERENCES

- Avery, R.L., D.J. Pieramicini, M.D. Rabena, A.C. Castellarin, M.A. Nasir, M.J. Giust, 2006. Intravitreal bevacizumab (Avastin) for neovascular age-related macular degeneration. *Ophthalmol*, 113: 363-372.
- Barros, L.F., R. Jr Belfort, 2007. The effects of the subconjunctival injection of bevacizumab [Avastin(R)] on angiogenesis in the rat cornea. *An Acad Bras Cienc.*, 79(3): 389-394.
- Boehm, M., A. Huang, 2004. Treatment of recurrent corneal and conjunctival intraepithelial neoplasia with topical interferon alfa 2b. *Ophthalmol*, 111: 1755-1761.
- Daniell, M., R. Maini, D. Tole, 2002. Use of mitomycin C in the treatment of corneal conjunctival intraepithelial neoplasia. *Clin Exp Ophthalmol*, 30: 94-98.
- DeStafeno, J. and T. Kim, 2007. Topical Bevacizumab Therapy for Corneal Neovascularization. *Arch Ophthalmol*, 125(6): 834-836.
- Dibbens, J.A., D.L. Miller, A. Damert, *et al.*, 1999. Hypoxic regulation of vascular endothelial growth factor mRNA stability requires the cooperation of multiple RNA elements. *Mol Biol Cell.*, 10: 907-919.
- Emmanouilides, C., M. Pegran, R. Robinson, R. Hecht, W. Isacoff, 2004. Anti-VEGF antibody bevacizumab (Avastin) with 5FU/LV as third line treatment for colorectal cancer. *Tech Coloproctol*, 8: s50-s52.
- Finger, T.F., 1998-2009. Available at: www.eyecancernetwork.com. Last accessed March 2009.
- Herbst, R.S., E. Mininberg, T. Henderson, *et al.*, 2003. Phase I/II trial evaluating blockade of tumor blood supply and tumor cell proliferation with combined bevacizumab and erlotinib HCl as targeted cancer therapy in patients with recurrent non-small cell lung cancer. *Eur J Cancer*, 1: S293.

Holcombe, D.J., G.A. Lee, 2006. Topical interferon alfa-2b for the treatment of recalcitrant ocular surface squamous neoplasia. *Am J Ophthalmol*, 142: 568–571.

Hosseini, H., M. Nejabat, M. Mehryar, T. Yazdchi, A. Sedaghat, F. Noori, 2007. Bevacizumab inhibits corneal neovascularization in an alkali burn induced model of corneal angiogenesis. *Clin. & Exp. Ophthalmol*, 35(8): 745–748.

Hurwitz, H., L. Fehrenbacher, W. Novotny, *et al.*, 2004. Bevacizumab plus irinotecan, fluorouracil, and leucovorin for metastatic colorectal cancer. *N Engl J Med.*, 350: 2335-2342.

Johnson, B.E., P. Ma, H. West, *et al.*, 2005. Preliminary phase II safety evaluation of ZD6474, in combination with carboplatin and paclitaxel as 1st line treatment in patients with NSCLC. *Proc Am Soc Clin Oncol*, 23: 7102.

Kabbinavar, F.F., J. Schulz, M. McCleod, *et al.*, 2005. Addition of bevacizumab to bolus fluorouracil and leucovorin in first-line metastatic colorectal cancer: results of a randomized phase II trial. *J Clin Oncol.*, 23: 3697–3705.

Kabbinavar, F.I., N.J. Meropol, G. Lieberman, S. Griffing, E. Bergsland, (2003): Phase II, randomized trial comparing bevacizumab plus fluorouracil (FU)/Leucovorin (LV) with FU/LV alone in patients with metastatic colorectal cancer. *J Clin Oncol.*, 21: 60-65.

Kim, K.J., B. Li, J. Winer, *et al.*, 1993. Inhibition of vascular endothelial growth factor-induced angiogenesis suppresses tumour growth *in vivo*. *Nature*, 362: 841–844.

Manzano R., G. Peyman, P. Khan, P. Carvounis, M. Kivilcim, M. Ren, J. Lake, P. Chévez-Barrios, 2007. Inhibition of experimental corneal neovascularisation by bevacizumab (Avastin). *Br. J. Ophthalmol*, 91: 804-807.

Michels, S., P.J. Rosenfeld, C.A. Pucoafito, E.N. Marcus, A.S. Venkatraman, 2005. Systemic bevacizumab (Avastin) therapy for neovascular age-related macular degeneration twelve-week results of an uncontrolled open-label clinical study. *Ophthalmol*, 112: 1035-1047.

Miller, K.D., L.I. Chap, F.A. Holmes, *et al.*, 2005. Randomized phase III trial of capecitabine compared with bevacizumab plus capecitabine in patients with previously treated metastatic breast cancer. *J Clin Oncol.*, 23: 792–799.

Prabhasawat, P., P. Tarinvorakup, N. Tesavibul, *et al.*, 2005. Topical 0.002% mitomycin C for the treatment of conjunctival-corneal intraepithelial neoplasia and squamous cell carcinoma. *Cornea.*, 24: 443–448.

Sandler, A., 2007. Bevacizumab in non small cell lung cancer. *Clin Cancer Res.*, 13(15 Pt 2): s4613-4616.

Shields, C.L., M. Naseripour, J.A. Shields, 2002. Topical mitomycin C for extensive, recurrent conjunctival–corneal squamous cell carcinoma. *Am J Ophthalmol*, 133: 601–606.